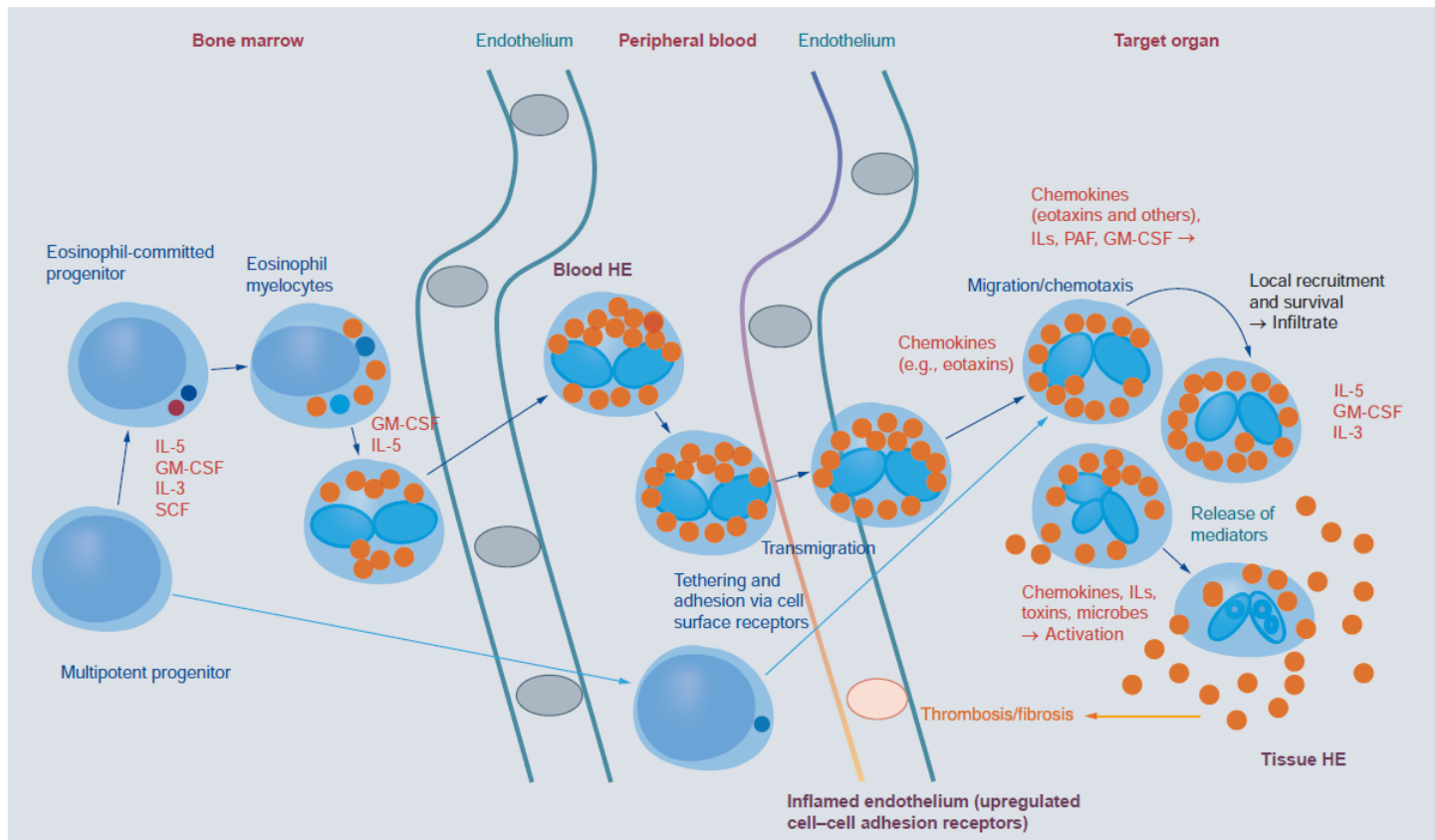


# Hyperéosinophilie



**Figure 1. Development of eosinophils and reactive hyper eosinophilia.** Eosinophils originate from multipotent and lineage-restricted hematopoietic progenitor cells. Eosinophil progenitors reside in the bone marrow but are also detectable in the peripheral blood. Eosinophil development is regulated by eosinophilopoietic cytokines (IL-3, GM-CSF and IL-5) and takes place primarily in the bone marrow. Cytokine-induced HE in the peripheral blood is often accompanied by tissue HE. Activation of eosinophils and activation of endothelial cells contribute to endothelial transmigration and infiltration of inflamed tissues. Eosinophil adhesion to endothelium and transmigration are mediated by certain homing receptors. Migration and accumulation of eosinophils in (inflamed) tissues are mediated by chemotactic peptides (chemokines), cytokines and other mediators. Eosinophil accumulation is also triggered by delayed eosinophil apoptosis, another cytokine-mediated phenomenon, in local tissue sites. Activation of eosinophils leads to degranulation and mediator secretion in tissues, with consequent organ damage, which may be accompanied by fibrosis and/or thrombosis and by deposition of eosinophil granule proteins.  
 HE: Hyper eosinophilia; GM-CSF: Granulocyte/macrophage colony-stimulating factor; IL: Interleukin; PAF: Platelet-activating factor; SCF: Stem cell factor.

# Définition

## Contemporary consensus proposal on criteria and classification of eosinophilic disorders and related syndromes

---

Peter Valent, MD,<sup>a</sup> Amy D. Klion, MD,<sup>b</sup> Hans-Peter Horny, MD,<sup>c</sup> Florence Roufousse, MD, PhD,<sup>d</sup> Jason Gotlib, MD,<sup>e</sup> Peter F. Weller, MD,<sup>f</sup> Andrzej Hellmann, MD,<sup>g</sup> Georgia Metzgeroth, MD,<sup>h</sup> Kristin M. Leiferman, MD,<sup>i</sup> Michel Arock, PharmD, PhD,<sup>j</sup> Joseph H. Butterfield, MD,<sup>k</sup> Wolfgang R. Sperr, MD,<sup>a</sup> Karl Sotlar, MD,<sup>l</sup> Peter Vandenberghe, MD, PhD,<sup>m</sup> Torsten Haferlach, MD,<sup>n</sup> Hans-Uwe Simon, MD, PhD,<sup>o</sup> Andreas Reiter, MD,<sup>h</sup> and Gerald J. Gleich, MD<sup>1,p</sup> *Vienna, Austria, Bethesda, Md, Ansbach, Mannheim, and Munich, Germany, Brussels and Leuven, Belgium, Stanford, Calif, Boston, Mass, Gdansk, Poland, Salt Lake City, Utah, Cachan, France, Rochester, Minn, and Bern, Switzerland*

Eosinophilia is an important indicator of various neoplastic and nonneoplastic conditions. Depending on the underlying disease and mechanisms, eosinophil infiltration can lead to organ dysfunction, clinical symptoms, or both. During the past 2 decades, several different classifications of eosinophilic disorders and related syndromes have been proposed in various fields of medicine. Although criteria and definitions are, in part, overlapping, no global consensus has been presented to date. The Year 2011 Working Conference on Eosinophil Disorders and Syndromes was organized to update and refine the criteria and definitions for eosinophilic disorders and to merge prior classifications in a contemporary multidisciplinary schema. A panel of experts from the fields of immunology, allergy, hematology, and pathology contributed to this project. The expert group agreed on unifying terminologies and criteria and a classification that delineates various forms of hypereosinophilia, including primary and secondary variants based on specific hematologic and immunologic conditions, and various forms of the hypereosinophilic syndrome. For patients in whom no underlying disease or hypereosinophilic syndrome is found, the term hypereosinophilia of undetermined significance is introduced. The proposed novel criteria, definitions, and terminologies should assist in daily practice, as well as in the preparation and conduct of clinical trials. (*J Allergy Clin Immunol* 2012;130:607-12.)

**Key words:** *Hypereosinophilic syndrome, eosinophilic leukemia, criteria, classification, hypereosinophilia of undetermined significance*

Eosinophilia is observed in patients with various inflammatory and allergic conditions, as well as diverse hematologic malignancies.<sup>1-3</sup> In hematopoietic stem cell and myeloid neoplasms, eosinophils originate from a malignant clone, whereas in other conditions and disorders, (hyper)eosinophilia is considered a non-neoplastic process triggered by eosinophilopoietic cytokines or by other as yet unknown processes.<sup>1-3</sup> Peripheral blood eosinophilia can be transient, episodic, or persistent. In patients with chronic (persistent) eosinophilia, tissue infiltration and the effects of eosinophil-derived effector molecules might result in clinically relevant organ pathology or even in (irreversible) organ damage.<sup>4-6</sup> Notably, among a range of effects on multiple organs, endomyocardial fibrosis, thrombosis, or both might be life-threatening consequences in patients with sustained eosinophilia. In other patients eosinophilia can be persistent but does not lead to measurable organ dysfunction. In these patients the clinical course and outcome remain uncertain; therefore they should be followed for potential disease progression.

Several neoplastic conditions are associated with eosinophilia. Myeloid neoplasms variably accompanied by eosinophilia are chronic myeloid leukemia (CML), other myeloproliferative

**TABLE I.** Definition of HE and HES

Proposed term	Proposed abbreviation	Definition and criteria
Blood eosinophilia	—	>0.5 Eosinophils $\times 10^9/L$ blood
Hypereosinophilia	HE	>1.5 Eosinophils $\times 10^9/L$ blood on 2 examinations (interval $\geq 1$ month*) and/or tissue HE defined by the following†: <ol style="list-style-type: none"> <li>1. Percentage of eosinophils in BM section exceeds 20% of all nucleated cells and/or</li> <li>2. Pathologist is of the opinion that tissue infiltration by eosinophils is extensive and/or</li> <li>3. Marked deposition of eosinophil granule proteins is found (in the absence or presence of major tissue infiltration by eosinophils).</li> </ol>
Hypereosinophilic syndrome	HES	<ol style="list-style-type: none"> <li>1. Criteria for peripheral blood HE fulfilled* and</li> <li>2. Organ damage and/or dysfunction attributable to tissue HE‡ and</li> <li>3. Exclusion of other disorders or conditions as major reason for organ damage.</li> </ol>
Eosinophil-associated single-organ diseases		<ol style="list-style-type: none"> <li>1. Criteria of HE fulfilled and</li> <li>2. Single-organ disease (see Table III and Tables E4 and E5 for specific entities)</li> </ol>

\*In the case of evolving life-threatening end-organ damage, the diagnosis can be made immediately to avoid delay in therapy.

†Validated quantitative criteria for tissue HE do not exist for most tissues at the present time. Consequently, tissue HES is defined by a combination of qualitative and semiquantitative findings that will require revision as new information becomes available.

‡HE-related organ damage (damage attributable to HE): organ dysfunction with marked tissue eosinophil infiltrates and/or extensive deposition of eosinophil-derived proteins (in the presence or absence of marked tissue eosinophils) and 1 or more of the following: (1) fibrosis (lung, heart, digestive tract, skin, and others); (2) thrombosis with or without thromboembolism; (3) cutaneous (including mucosal) erythema, edema/angioedema, ulceration, pruritus, and eczema; and (4) peripheral or central neuropathy with chronic or recurrent neurologic deficit. Less commonly, other organ system involvement (liver, pancreas, kidney, and other organs) and the resulting organ damage can be judged as HE-related pathology, so that the clinician concludes the clinical situation resembles HES. Note that HES can manifest in 1 or more organ systems.

# Eosinophilie sanguine

= augmentation du chiffre des polynucléaires  
éosinophiles sanguins à  $> 500/\text{mm}^3$

# Hyperéosinophilie

- augmentation du chiffre des polynucléaires éosinophiles sanguins à  $> 1.500/\text{mm}^3$  sur deux examens séparés d'au moins un mois

et/ou

- hyperéosinophilie tissulaire
  - $> 20\%$  éosinophiles moelle osseuse
  - infiltration tissulaire étendue sur une biopsie
  - dépôts tissulaires de protéines des granules des éosinophiles

# Syndrome hyperéosinophilique

## Association

- Hyperéosinophilie
- Dysfonction ou lésions d'un organe cible par les éosinophiles

y compris si la cause de l'hyperéosinophilie est connue (ex, endocardite de Loeffler)

**TABLE E4.** Organ-restricted (inflammatory) conditions accompanied by HE\*

---

Eosinophilic gastrointestinal disorders

Eosinophilic esophagitis

Eosinophilic gastroenteritis

Eosinophilic colitis

Eosinophilic pancreatitis

Eosinophilic hepatitis

Eosinophilic ascites

Pulmonary eosinophilic syndromes

Eosinophilic asthma

Eosinophilic bronchitis

Eosinophilic pneumonia

Eosinophilic pleuritis

Eosinophilic nephritis

Eosinophilic cystitis

Eosinophilic endometritis and myometritis

Eosinophilic mastitis

Eosinophilic ocular disorders

Eosinophilic myocarditis

Eosinophilic panniculitis

Eosinophilic synovitis

Eosinophilic fasciitis (Shulman syndrome)

Dermatologic conditions/diseases†

---



**TABLE E5.** Dermatologic diseases accompanied by eosinophilia\*

---

Allergic contact dermatitis
Angiolymploid hyperplasia with eosinophilia
Annular erythema of infancy
Atopic dermatitis
Bullous pemphigoid
Coccidiomycosis
Drug eruptions
Eosinophilic fasciitis
Eosinophilic, polymorphic, and pruritic eruption associated with radiotherapy
Eosinophilic pustular folliculitis: all variants
Erythema toxicum neonatorum
Eosinophilic ulcer of the oral mucosa
Eosinophilic vasculitis
Granuloma faciale
Infestations (parasites/ectoparasites, including scabies, bed bugs, and cutaneous larva migrans)
Incontinentia pigmenti
Kimura disease
Langerhans cell histiocytosis
Mycosis fungoides and Sézary syndrome
Pachydermatous eosinophilic dermatitis
Pemphigoid variants, including bullous pemphigoid and pemphigoid gestationis
Pemphigus variants
Pregnancy-related dermatoses
Pseudolymphoma
Urticaria/angioedema
Vasculitis
Wells syndrome (eosinophilic cellulitis)

---

# Les catégories d'hyperéosinophilie

**TABLE II.** Classification of HE

Proposed terminology	Proposed abbreviation	Pathogenesis/definition
Hereditary (familial) HE	HE <sub>FA</sub>	Pathogenesis unknown; familial clustering, no signs or symptoms of hereditary immunodeficiency, and no evidence of a reactive or neoplastic condition/disorder underlying HE
HE of undetermined significance	HE <sub>US</sub>	No underlying cause of HE, no family history, no evidence of a reactive or neoplastic condition/disorder underlying HE, and no end-organ damage attributable to HE
Primary (clonal/neoplastic) HE†	HE <sub>N</sub>	Underlying stem cell, myeloid, or eosinophilic neoplasm, as classified by WHO criteria; eosinophils considered neoplastic cells*
Secondary (reactive) HE‡	HE <sub>R</sub>	Underlying condition/disease in which eosinophils are considered nonclonal cells‡; HE considered cytokine driven in most cases‡

\*Clonality of eosinophils is often difficult to demonstrate or is not examined. However, if a myeloid or stem cell neoplasm known to present typically with clonal HE is present or a typical molecular defect is demonstrable (eg, *PDGFR* or *FGFR* mutations or *BCR/ABL1*), eosinophilia should be considered clonal.

†HE<sub>N</sub> and HE<sub>R</sub> are prediagnostic checkpoints that should guide further diagnostic evaluations but cannot serve as final diagnoses.

‡In a group of patients, HE<sub>R</sub> might be caused/triggered by other as yet unknown processes because no increase in eosinophilopoietic cytokine levels can be documented.

**TABLE E2.** Causes of reactive eosinophilia/HE\*

---

Common causes
Helminth infections
Allergic reactions
Atopic diseases
Drug reactions (allergic or toxic)
Rare causes
Chronic graft-versus-host disease
Hodgkin disease
B- or T-cell lymphoma/leukemia
Langerhans cell histiocytosis
Indolent systemic mastocytosis
Solid tumors/malignancy
Scabies, other infestations
Allergic bronchopulmonary aspergillosis
Chronic inflammatory disorders (eg, IBD)
Autoimmune diseases

---

*IBD*, Inflammatory bowel disease.

\*In most cases eosinophilia is attributable to eosinophilopoietic cytokines.

**Table 4. Examples of rare syndromes accompanied by eosinophilia.**

Syndrome	Characteristics
Gleich's syndrome	Cyclic recurrent angioedema and elevated IgM, sometimes with clonal T cells
Churg–Strauss syndrome	Necrotizing vasculitis with eosinophilia (ANCA <sup>+</sup> and ANCA <sup>-</sup> subvariants)
Eosinophilia myalgia syndrome	Severe myalgia, often accompanied by neurologic symptoms and skin changes; epidemic cases have been attributed to L-tryptophan exposure (subvariant: toxic oil syndrome)
Omenn syndrome	Severe combined immunodeficiency plus HE, often with erythroderma, hepatosplenomegaly or lymphadenopathy, autosomal recessive genetic disease (recurrent mutations in <i>RAG1</i> or <i>RAG2</i> )
Hyper-IgE syndrome	Hereditary immunodeficiency syndrome with HE and elevated levels of IgE, often with eczema and facial anomalies. Known gene mutations – autosomal dominant variant: <i>STAT3</i> mutations; autosomal recessive variant: <i>DOCK8</i> mutations

ANCA: Antineutrophil cytoplasmic antibodies; HE: Hypereosinophilia.

## **GRANULOMATOSE ÉOSINOPHILE AVEC POLYANGÉITE\*** **Critères de l'American College of Rheumatology (1990)**

**Chez un sujet atteint de vascularite, la présence de 4 des 6 critères suivants permet le classement comme granulomatose éosinophile avec polyangéite**

- Asthme
- Éosinophilie sanguine  $\geq 10\%$
- Antécédent d'allergie
- Infiltrats pulmonaires labiles
- Douleur ou opacité sinusienne
- Présence d'éosinophiles extravasculaires à la biopsie

**Tableau 7.** \* Anciennement syndrome de Churg et Strauss.

## VASCULARITES DES PETITS VAISSEAUX À COMPLEXES IMMUNS

- ✗ Vascularites cryoglobulinémiques
- ✗ Vascularites à dépôts d'IgA : purpura rhumatoïde = purpura de Henoch-Schönlein
- ✗ Vascularites à dépôts d'anticorps antimembrane basale glomérulaire (Goodpasture)
- ✗ Vascularites urticariennes hypocomplémentémiques (à anticorps anti-C1q) de Mac Duffie

## VASCULARITES DES VAISSEAUX DE TAILLE MOYENNE

- ✗ Périartérite noueuse
- ✗ Maladie de Kawasaki

## VASCULARITES ASSOCIÉES AUX ANCA

- ✗ Granulomatose avec polyangéite (GPA, anciennement maladie de Wegener)
- ✗ Micropolyangéite (MPA)
- ✗ Granulomatose à éosinophiles avec polyangéite (EGPA) [anciennement angéite de Churg et Strauss]

## VASCULARITES DES VAISSEAUX DE GRANDE TAILLE

- ✗ Maladie de Horton
- ✗ Maladie de Takayasu

**Figure 1. Classification des vascularites selon la taille des vaisseaux atteints.** D'après Jennette JC, Falk RJ, Bacon PA, et al. 2012 revised International Chapel Hill Consensus Conference Nomenclature of Vasculitides. Arthritis Rheum 2013;65(1):1-11

## Diagnostic différentiel du syndrome de Churg et Strauss avec les autres vascularites systémiques

MANIFESTATIONS CLINIQUES	SYNDROME DE CHURG ET STRAUSS	GRANULOMATOSE DE WEGENER	POLYANGÉITE MICROSCOPIQUE	PÉRIARTÉRITE NOUEUSE
Antécédents d'allergie	++++	0	0	0
Asthme	++++	0	0	0
Atteinte pulmonaire	+++	+++	++	0
Multinévrite	+++	+	++	++++
Atteinte digestive	+++	±	++	+++
Atteinte cardiaque	++	+	+	+
Atteinte oto-rhino-laryngée	++	+++	+	±
Atteinte articulaire	++	++	++	++
Glomérulonéphrite	+	+++	++++	0
Hypertension artérielle	±	+	++	+++
Atteinte ophtalmologique	+	++	++	+
Hyperéosinophilie	++++	±	0	±
p-ANCA	++	+	+++	±
c-ANCA	0	++++	+	0
Microanévrismes à l'artériographe	±	0	0	++

Tableau 3

# Pathophysiologie



# mécanismes pathogéniques

- processus **réactionnel inflammatoire** local (invasion parasitaire) ou systémique (allergie médicamenteuse), médié par une augmentation non spécifique des diverses cytokines régulatrices de la production médullaire de l'éosinophile (GM-CSF, IL-3, IL-5)
- processus **prolifératif clonal** soit de l'éosinophile lui-même (FIPALI-PDGFRA), soit de cellules productrices de la cytokine majeure de sa régulation, en l'occurrence le lymphocyte T sécrétant de l'IL-5

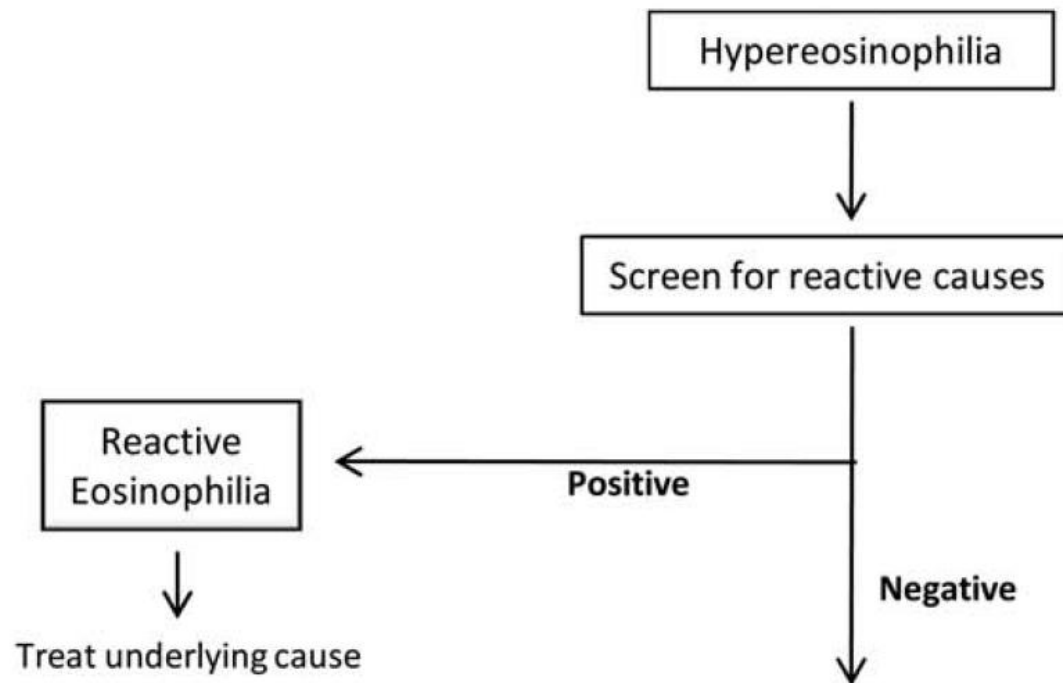
# Conséquences

Lésions des tissus infiltrés:

- Peau
- Poumons
- Tube digestif
- Appareil cardiovasculaire
- Système nerveux
- ...

# Diagnostic

# I. Éosinophilie réactionnelle



# Hyperéosinophilies secondaires (réactionnelles)

- 1) l'atopie
- 2) les allergies médicamenteuses
- 3) les causes toxiques
- 4) les causes parasitaires
- 5) les causes dermatologiques
- 6) les causes digestives
- 7) les causes pulmonaires
- 8) certains déficits immunitaires
- 9) certaines maladies systémiques
- 10) certaines néoplasies solides ou hématologiques

## Principales causes d'hyperéosinophilie secondaire

### Atopie

- Asthme
- Allergies diverses

### Médicaments, y compris DRESS

- Bêtalactamines
- Anti-inflammatoires non stéroïdiens
- Allopurinol
- Sulfamides hypoglycémiants

### Toxiques

- Huile toxique (Espagne)
- L-tryptophane

### Parasitoses

- Helminthiases
- Téniasis
- Hydatidose
- Bilharzioses
- Filarioses

### Dermatoses non allergiques

- Pemphigoïde bulleuse
- Mastocytose

### Affections digestives

- Maladie de Whipple
- Maladie de Crohn

### Affections pulmonaires

- Aspergillose bronchopulmonaire allergique
- Maladie de Carrington

### Déficits immunitaires

- Syndrome de Wiskott-Aldrich
- Syndrome de Job-Buckley

### Maladies systémiques

- Polyarthrite rhumatoïde
- Lupus érythémateux disséminé
- Polymyosite

- Fasciite à éosinophiles (Shulman)

- Angéite de Churg-Strauss

- Périartérite noueuse

- Maladie de Wegener

- Emboles de cristaux de cholestérol

- Syndrome de Wells

- Brûlures étendues

- Radiothérapie

- Insuffisance surrénale

- Splénectomie ou asplénie fonctionnelle

- GVH post-allogreffe médullaire

- Syndrome hyper-IgG4

### Affections tumorales hématologiques ou solides

- Lymphome de Hodgkin

- Lymphomes T

- Cancers :

→ bronchopulmonaire,

→ utérin,

→ gastrique,

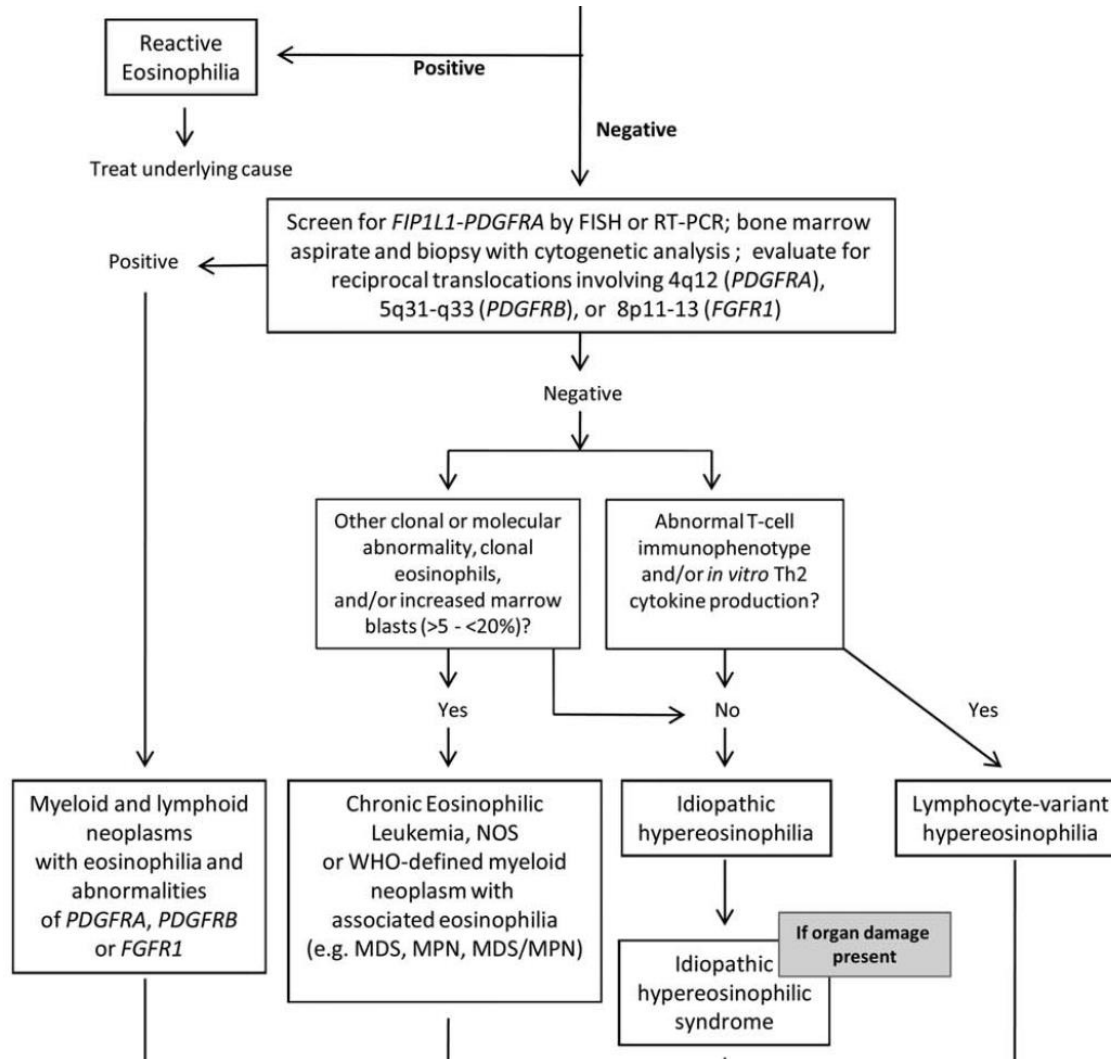
→ colique...

DRESS : *Drug Reaction with Eosinophilia and Systemic Symptoms* ; GVH : réaction du greffon contre l'hôte.

## Principales causes parasitaires d'hyperéosinophilie

Parasitoses cosmopolites	Parasitoses tropicales	
	Type de parasite	Localisation géographique
<b>Toxocarose</b>	<ul style="list-style-type: none"> <li>■ Ankylostomose</li> <li>■ Anguillulose</li> </ul>	<ul style="list-style-type: none"> <li>■ Pays tropicaux et subtropicaux</li> </ul>
<b>Trichinose</b>	<ul style="list-style-type: none"> <li>■ Bilharzioses : <ul style="list-style-type: none"> <li>→ urinaire</li> <li>→ intestinale</li> </ul> </li> <li>→ rectale</li> </ul>	<ul style="list-style-type: none"> <li>■ Afrique, Moyen-Orient</li> <li>■ Afrique, Amérique centrale et du Sud, Antilles, Extrême-Orient, Laos, Thaïlande, Cambodge</li> <li>■ Afrique équatoriale</li> </ul>
<b>Distomatose hépatique (en cas de fissuration du kyste)</b>	<ul style="list-style-type: none"> <li>■ Distomatoses : <ul style="list-style-type: none"> <li>→ intestinale</li> <li>→ pulmonaire et cérébrale (paragonimose)</li> </ul> </li> </ul>	<ul style="list-style-type: none"> <li>■ Asie, Égypte</li> <li>■ Asie, Amérique</li> </ul>
<b>Ascarirose</b>	<ul style="list-style-type: none"> <li>■ Filarioses : <ul style="list-style-type: none"> <li>→ loase</li> <li>→ dracunculose</li> <li>→ onchocercose</li> <li>→ lymphatiques</li> </ul> </li> </ul>	<ul style="list-style-type: none"> <li>■ Afrique centrale et de l'Ouest</li> <li>■ Afrique, Asie</li> <li>■ Afrique intertropicale, foyers américain et asiatique</li> <li>■ Zones inter- et subtropicale</li> </ul>
<b>Téniases</b>	<ul style="list-style-type: none"> <li>■ Anisakiase</li> </ul>	<ul style="list-style-type: none"> <li>■ Japon</li> </ul>

# II. Hyperéosinophilies primitives





**TABLE II.** 2008 World Health Organization Classification of Eosinophilic Disorders

**Myeloid and lymphoid neoplasms with eosinophilia and abnormalities of *PDGFRA*, *PDGFRB*, or *FGFR1***

**Diagnostic criteria of an MPN<sup>a</sup> with eosinophilia associated with *FIP1L1-PDGFRB***

A myeloproliferative neoplasm with prominent eosinophilia

AND

Presence of a *FIP1L1-PDGFRB* fusion gene<sup>b</sup>

**Diagnostic criteria of MPN associated with *ETV6-PDGFRB* fusion gene or other rearrangement of *PDGFRB***

A myeloproliferative neoplasm, often with prominent eosinophilia and sometimes with neutrophilia or monocytosis

AND

Presence of t(5;12)(q31~q33;p12) or a variant translocation<sup>c</sup> or, demonstration of an *ETV6-PDGFRB* fusion gene or rearrangement of *PDGFRB*

**Diagnostic criteria of MPN or acute leukemia associated with *FGFR1* rearrangement**

A myeloproliferative neoplasm with prominent eosinophilia and sometimes with neutrophilia or monocytosis

OR

Acute myeloid leukemia or precursor T-cell or precursor B-cell lymphoblastic leukemia/lymphoma (usually associated with peripheral blood or bone marrow eosinophilia)

AND

Presence of t(8;13)(p11;q12) or a variant translocation leading to *FGFR1* rearrangement demonstrated in myeloid cells, lymphoblasts, or both

**Chronic Eosinophilic Leukemia, Not Otherwise Specified (NOS)**

1. There is eosinophilia (eosinophil count  $>1.5 \times 10^9/L$ )
2. There is no Ph chromosome or *BCR-ABL* fusion gene or other myeloproliferative neoplasms (PV, ET, PMF, systemic mastocytosis) or MDS/MPN (CMML or atypical CML)
3. There is no t(5;12)(q31~q35;p13) or other rearrangement of *PDGFRB*
4. There is no *FIP1L1-PDGFRB* fusion gene or other rearrangement of *PDGFRA*
5. There is no rearrangement of *FGFR1*
6. The blast cell count in the peripheral blood and bone marrow is less than 20% and there is no inv(16)(p13q22) or t(16;16)(p13;q22) or other feature diagnostic of AML
7. There is a clonal cytogenetic or molecular genetic abnormality, or blast cells are more than 2% in the peripheral blood or more than 5% in the bone marrow.

**Idiopathic Hypereosinophilic Syndrome (HES)**

Exclusion of the following:

1. Reactive eosinophilia
2. Lymphocyte-variant hypereosinophilia (cytokine-producing, immunophenotypically aberrant T-cell population)
3. Chronic eosinophilic leukemia, NOS
4. WHO-defined myeloid malignancies associated eosinophilia (e.g., MDS, MPNs, MDS/MPNs, or AML)
5. Eosinophilia-associated MPNs or AML/ALL with rearrangements of *PDGFRA*, *PDGFRB*, or *FGFR1*.
6. The absolute eosinophil count of  $>1,500/mm^3$  must persist for at least 6 months and tissue damage must be present. If there is no tissue damage, idiopathic hypereosinophilia is the preferred diagnosis.

**TABLE I.** 2008 World Health Organization (WHO) Classification of Myeloid Malignancies

1. Acute myeloid leukemia and related disorders
2. Myeloproliferative neoplasms (MPN)
  - Chronic myelogenous leukemia, *BCR-ABL1* positive
  - Chronic neutrophilic leukemia
  - Polycythemia vera
  - Primary myelofibrosis
  - Essential thrombocythemia
  - Chronic eosinophilic leukemia, not otherwise specified
  - Mastocytosis
  - Myeloproliferative neoplasms, unclassifiable
3. Myelodysplastic syndromes (MDS)
  - Refractory cytopenia with uni-lineage dysplasia
    - Refractory anemia
    - Refractory neutropenia
    - Refractory thrombocytopenia
  - Refractory anemia with ring sideroblasts
  - Refractory cytopenia with multilineage dysplasia
  - Refractory anemia with excess blasts (RAEB)
    - RAEB-1
    - RAEB-2
  - Myelodysplastic syndrome with isolated del(5q)
  - Myelodysplastic syndrome, unclassifiable
4. MDS/MPN
  - Chronic myelomonocytic leukemia
    - CMML-1
    - CMML-2
  - Atypical chronic myeloid leukemia, *BCR-ABL1* negative
  - Juvenile myelomonocytic leukemia
  - MDS/MPN, unclassifiable
    - Refractory anemia with ring sideroblasts and thrombocytosis (RARS-T)
5. Myeloid and lymphoid neoplasms associated with eosinophilia and abnormalities of *PDGFRA*, *PDGFRB*, or *FGFR1*
  - Myeloid and lymphoid neoplasms associated with *PDGFRA* rearrangement
  - Myeloid neoplasms associated with *PDGFRB* rearrangement
  - Myeloid and lymphoid neoplasms associated with *FGFR1* abnormalities.

## PRINCIPALES HÉMOPATHIES MYÉLOÏDES CLONALES AVEC HYPERÉOSINOPHILIES (SHE NÉOPLASIQUES OU CLONAUX)

**Néoplasie myéloïde avec HE constante et anomalie génétique récurrente**

- Délétion *FIP1L1-PDGFRRA* et translocations impliquant PDGFRA
- Translocations impliquant PDGFRA
  - Translocations impliquant FGFR1 (leucémie-lymphome)
  - Translocations impliquant FLT3 (leucémie aiguë myéloïde)

**Néoplasie myéloïde définie (OMS) avec HE inconstante**

- Leucémie myéloïde chronique BCR-ABL
- Mutation JAK2 V617F
- Mastocytose systémique KIT avec hyperéosinophilie
- Leucémie aiguë à éosinophiles CFBF-MYH11 : LAM4-Eo, LAM inv(16)
- Syndromes myélodysplasiques avec HE
- Autres néoplasies myéloïdes définies avec HE

**Néoplasie myéloïde avec HE et anomalie génétique non récurrente**

- Critère d'exclusion : néoplasies myéloïdes définies ci-dessus, leucémies aiguës, autres syndromes hyperéosinophiliques
- Blastés < 2 % dans le sang et < 20 % dans la moelle
- Présence d'autres(s) anomalie(s) cytogénétique(s) non spécifique(s) (telles trisomie 8; isochromosome 17), et/ou d'anomalies en séquençage haut débit (NGS)

**Tableau 3.** ABL : Abelson ; BCR : *breakpoint cluster region* ; CFBF : *core-binding factor subunit beta* ; FGFR1 : *fibroblast growth factor receptor 1* ; FIP1L1 : *factor interacting with PAPOLA and CPSF1* ; FLT3 : *Fms-like tyrosine kinase 3* ; HE : hyperéosinophilie ; JAK2 : Janus kinase 2 ; KIT : *tyrosine-protein kinase kit* ; LAM : leucémie aiguë myéloblastique ; MYH11 : *myosin heavy chain 11* ; NGS : *next-generation sequencing* ; OM : Organisation mondiale de la santé ; PDGFRA : *platelet-derived growth factor receptor alpha* ; PCM1 : *pericentriolar material 1* ; SHE : syndrome hyperéosinophilique.

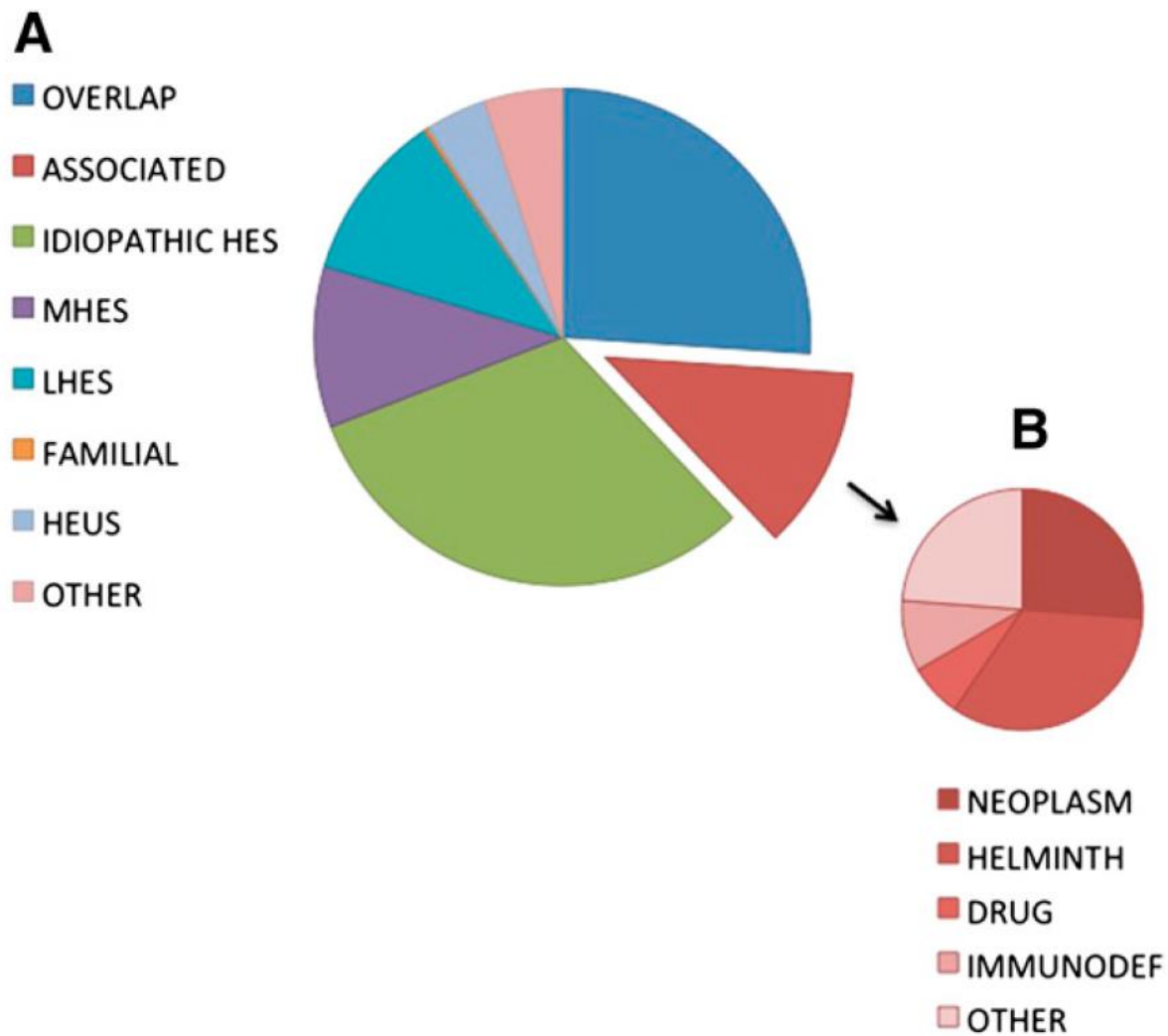
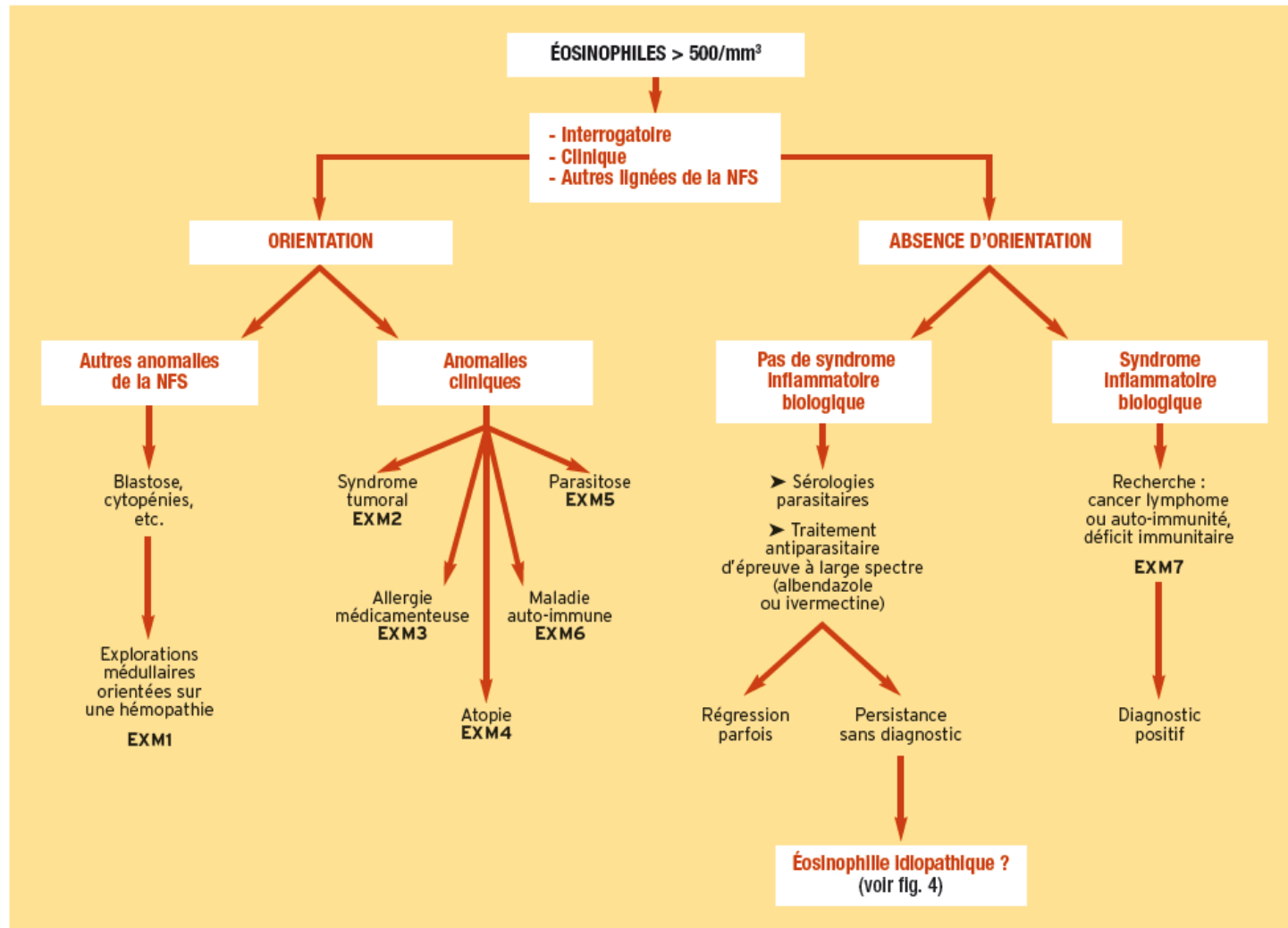


Figure 2. Frequency distribution of diagnoses in a cohort of 302 subjects referred for evaluation of unexplained hyper eosinophilia.

# Bilan

# Démarche diagnostique: pistes



## a. importante éosinophilie et autres anomalies de l'hémogramme

Penser à une leucémie aiguë myéloblastique de type 4 ou une leucémie à éosinophiles:

- myélogramme
- caryotype
- biologie moléculaire

## b. syndrome tumoral

évoquer une tumeur maligne, solide ou hématologique :

- iconographie adaptée au contexte
- biopsie ou ponction d'organe avec histologie



## c. suspicion d'allergie médicamenteuse

interrogatoire à la recherche de critères  
chronologiques d'imputabilité

- bilan rénal et hépatique
- recherche d'un DRESS (syndrome d'hypersensibilité médicamenteuse)

Table III. Drug-induced eosinophilic syndromes.

Manifestation	Drugs
Generalised rash with or without fever	Any drug is a possibility Mostly seen with antibiotics
Interstitial nephritis with eosinophiluria	Antibiotics, gold compounds, allopurinol
Pulmonary infiltrates	Nitrofurantoin, minocycline, naproxen, penicillins, phenylbutazone, sulindac, piroxicam, sulphonamides, nimesulide, tolfenamic acid
Pleuropulmonary manifestations	Dantrolene sodium, bleomycin, methotrexate
Hepatitis	Phenothiazines, penicillins, tolbutamide, allopurinol, methotrexate, fluoroquinolones
Leucocytoclastic vasculitis	Allopurinol, phenytoin
Chronic rhinosinusitis with nasal polyposis and asthma	Aspirin
Eosinophilia-myalgia syndrome	L-tryptophan
DRESS syndrome (drug rash with eosinophilia and systemic symptoms)	Carbamazepine, allopurinol, antibiotics, etc.

# Néphropathie interstitielle

TABLEAUX CLINICO-BIOLOGIQUES EN FONCTION DU COMPARTIMENT RÉNAL IMPLIQUÉ				
Compartiment	Clinique	Protéinurie	Sédiment	Autres
Vasculaire	Hypertension	< 1 g/g de créatinine sur échantillon	Hématurie	Stigmates de micro-angiopathie thrombotique
Glomérulaire	Œdèmes Signes extrarénaux	> 1 g/g avec > 50 % d'albumine	Hématurie abondante (> 200 GR/μL d'urine) avec cylindres hématiques	Hypo-albuminémie
Tubulo-interstitiel	Polyurie Signes extrarénaux	< 1 g/g	Leucocyturie aseptique	Troubles ioniques (syndrome de Fanconi, hypomagnésémie...) Hyperéosinophilie si allergie
Tubulaire seul (NTA)	Hypotension ou prise de néphrotoxique	< 1 g/g	Inactif (ni hématurie abondante ni leucocyturie)	

**Tableau 3.** GR : globules rouges ; NTA : nécrose tubulaire aiguë.

**TABLEAU 2. INSUFFISANCE RÉNALE ET MÉDICAMENTS : TOXICITÉ OU ALLERGIE ?**

En faveur de la toxicité	En faveur de l'allergie
Facteur de risque	Terrain allergique
Dose-dépendance	Toxicité non liée à la dose ou la durée de l'exposition
Aggravation progressive	Survenue brutale
Pas de signes extrarénaux	Réintroduction
Médicament intrinsèquement toxique	Médicaments potentiellement « allergisant »

## DIFFÉRENTS MÉCANISMES ET CAUSES DES NÉPHROPATHIES TUBULO-INTERSTITIELLES AIGÜES

Type	Mécanisme	Cause
Nécrose tubulaire aiguë ischémique	Hypoperfusion rénale	<ul style="list-style-type: none"> <li>– Choc vasoplégique ou hypovolémique</li> <li>– Syndrome cardiorénal ou hépatorénal</li> </ul>
Néphropathies médicamenteuses/toxiques	Toxicité directe	<ul style="list-style-type: none"> <li>– Aminosides</li> <li>– Produits de contraste iodés</li> <li>– Chimiothérapies (sels de platine, ifosfamide)</li> <li>– Antiviraux (ténofovir, cidofovir)</li> <li>– Anticalcineurines</li> <li>– Champignons (cortinaires)</li> <li>– Acide aristolochique</li> </ul>
	Immuno-allergique	<ul style="list-style-type: none"> <li>– Bêtalactamines</li> <li>– IPP</li> <li>– Fluoroquinolones</li> <li>– AINS, allopurinol . . .</li> </ul>
	Précipitation intra-tubulaire	<ul style="list-style-type: none"> <li>– Sulfadiazine</li> <li>– Amoxicilline</li> <li>– Antiviraux (aciclovir, indinavir, atazanavir)</li> <li>– Préparation colique (phosphate de calcium)</li> <li>– Éthylène-glycol</li> </ul>

Néphropathie par toxique endogène	Toxicité directe	<ul style="list-style-type: none"> <li>– Rhabdomyolyse</li> <li>– Hémolyse</li> <li>– Cholestase ictérique</li> </ul>
	Précipitation intra-tubulaire	<ul style="list-style-type: none"> <li>– Tubulopathie myélomateuse</li> <li>– Néphropathie oxalique</li> <li>– Syndrome de lyse tumorale</li> </ul>
Néphropathie d'origine infectieuse	Bactérienne	<ul style="list-style-type: none"> <li>– Pyélonéphrite</li> <li>– Infection hématogène</li> <li>– Leptospirose</li> <li>– Mycobactéries</li> </ul>
	Virale	<ul style="list-style-type: none"> <li>– Hantavirus</li> <li>– Polyomavirus (BK virus)</li> <li>– VIH</li> <li>– Autres (CMV, EBV...)</li> </ul>
	Fongique/parasitaire	<ul style="list-style-type: none"> <li>– Candidose disséminée</li> <li>– Histoplasmose, toxoplasmose, leishmaniose</li> </ul>
Néphropathie interstitielle immunologique	Auto-immunité	<ul style="list-style-type: none"> <li>– Syndrome de Gougerot-Sjögren</li> <li>– Sarcoïdose</li> <li>– Syndrome TINU</li> <li>– Maladie à IgG4</li> </ul>
	Allo-immunité	<ul style="list-style-type: none"> <li>– Rejet cellulaire (transplantation rénale)</li> </ul>
Néphropathie interstitielle néoplasique	Hémopathie	<ul style="list-style-type: none"> <li>– Lymphome malin et maladie de Waldenström</li> <li>– Lymphoprolifération post-transplantation</li> </ul>
	Cancer solide	<ul style="list-style-type: none"> <li>– Métastases rénales</li> </ul>

## MÉDICAMENTS IMPLIQUÉS DANS LES NÉPHROPATHIES INTERSTITIELLES AIGÜES EN FRANCE

Classes thérapeutiques	Nombre (%)
<b>Antibiotiques</b> tazobactam-pipéracilline + clindamycine, ciprofloxacine, rifampicine (2), ceftriaxone, amoxicilline-acide clavulanique, amoxicilline, imipénem, cefpodoxime, nitrofurantoïne, amoxicilline-acide clavulanique + érythromycine, oxacilline, cloxacilline.	14 (30,4 %)
<b>Fluindione</b>	11 (23,9 %)
<b>AINS</b> ibuprofène (3), diclofénac + ibuprofène, ibuprofène (+ rabéprazole), kétoprofène (+ ésoméprazole), kétoprofène (2), kétoprofène + naproxène, diclofénac (2)	11 (23,9 %)
<b>IPP</b> ésoméprazole (+ furosémide), ésoméprazole (2), oméprazole, rabéprazole, pantoprazole	6 (13 %)
<b>Autres</b> furosémide, vémurafénib, vildagliptine, warfarine	4 (8,7 %)

**Tableau 2.** Résultat de l'étude de la Société de néphrologie de l'Ouest 2012-2014 portant sur 46 cas.  
 AINS : anti-inflammatoires non stéroïdiens ; IPP : inhibiteurs de la pompe à protons.

# DRESS : Drug Reaction with Eosinophilia and Systemic Symptoms

= toxidermie survenant deux à six semaines après l'initiation d'une nouvelle molécule

## Tableau clinique

- touche surtout les afro-antillais
- état général très altéré, contexte pseudogrippal
- rash (pas toujours) : peu spécifique, pouvant toucher plus de la moitié de la surface corporelle
- œdème de la face avec respect des muqueuses, infiltration cutanée secondaire à l'œdème
- adénopathies
- forte fièvre
- hyperéosinophilie
- lymphocytes atypiques circulants
- présence d'au moins une atteinte viscérale : hépatique (cytolyse), rénale (néphrite tubulo- interstitielle), pulmonaire (pneumopathie interstitielle à éosinophiles), cardiaque, pancréatique, thyroïdienne, cérébrale (méningo-encéphalite), état de choc non septique, syndrome d'activation macrophagique



# DRESS suite

## Médicaments en cause

- antiépileptiques
- allopurinol
- minocycline
- sulfamidés
- ...

## Biologie

- hyperéosinophile
- syndrome mononucléosique
- PCR HHV6 (le syndrome surviendrait grâce à une réactivation virale d'un virus du groupe herpétique)

## Évolution

- dure au moins deux semaines
- peut s'étaler par vagues sur un an

## Traitement

- dermocorticoïdes de très forte classe
- dans les formes menaçantes : corticothérapie par voie générale, voire étoposide, IgG

## d. suspicion d'atopie

- antécédents d'asthme ou de rhinite
- tests allergologiques avec prick-test
- épreuves fonctionnelles respiratoires
- RAST (radioallergosorbent test)
- test de provocation

## e. suspicion d'une parasitose

selon le contexte géographique et clinique :

- scotch test anal (oxyurose ou tæniase)
- examen parasitologique des selles 3 jours de suite et si besoin enrichissement selon la technique de Baermann (anguillulose)
- sérologie toxocarose ou larva migrans
- sérologie distomatose
- sérologie hydatidose
- biopsie digestive ou analyse du contenu duodéal (helminthiases)
- anatomopathologie du sédiment urinaire ou des biopsies hépatiques ou rectales (bilharzioses)
- échographie hépatique ou scanner hépatique, pulmonaire ou cérébral (hydatidoses, cysticercoses)
- frottis sanguin, biopsie cutanée ou sérologies (filarioses)

Table II. Parasitosis associated with eosinophilia.

Disease/agent	Clinical features	Geographical distribution	Treatment
Lymphatic filariasis (roundworm)	Elephantiasis Pulmonary tropical eosinophilia	Tropics, subtropics, Asia	Diethylcarbamazine Ivermectin
<i>Loa loa</i> filariasis (roundworm)	Subconjunctival worms Skin lesions, episodic angioedema	Western Africa	Diethylcarbamazine
<i>Onchocerca</i> filariasis (roundworm)	Skin nodules Blindness	Africa, Latin America	Ivermectin
Gnathostomiasis (roundworm)	Cutaneous larva migrans Visceral larva migrans (meningitis)	Asia, Mexico	Albendazole Ivermectin
Anisakiasis (roundworm)	Acute abdominal pain	Worldwide Raw fish ingestion	Endoscopic removal of larvae
Hookworm (roundworm)	Iron deficiency anaemia	Worldwide	Albendazole
<i>Ancylostoma duodenale</i>		Africa, Asia, the Americas	Mebendazole
<i>Necator americanus</i>		Australia, Middle East	Pyrantel pamoate
Ascariasis (roundworm)	Abdominal pain, oral expulsion Intestinal or biliary obstruction Loeffler syndrome (pneumonitis)	Worldwide Tropics, Subtropics Rural southeastern US	Albendazole Mebendazole Pyrantel pamoate
Strongyloidiasis (roundworm)	Frequently asymptomatic Abdominal pain, diarrhoea Loeffler syndrome (pneumonitis)	Worldwide Tropics, Subtropics Rural South US	Ivermectin Albendazole
Trichinosis (roundworm)	Intestinal symptoms, myositis myocarditis, conjunctivitis	Worldwide Europe, US	Mebendazole Albendazole
Toxocariasis (roundworm)	Visceral and ocular larva migrans	Worldwide	Albendazole Mebendazole
Angiostrongyliasis (roundworm)	Eosinophilic meningitis	Southeast Asia Pacific Basin	No effective treatment
Paragonimiasis (lung fluke)	Pneumonia, rusty sputum Haemoptysis, skin lesions	Far East, Asia, Latin America, Africa	Praziquantel
Fascioliasis (liver fluke)	Hepatitis, hepatomegaly Biliary obstruction	Worldwide Raw watercress ingestion	Triclabendazole
Schistosomiasis			
<i>Haematobium</i>	Haematuria, bladder cancer	Africa, Middle East	Praziquantel
<i>Mansoni</i>	Portal hypertension	Latin America, Caribbean	Oxamniquine
<i>Japonicum</i>	Portal hypertension	Far East	Praziquantel
Isosporiasis (coccidian parasite)	Chronic diarrhoea	Worldwide immunocompromised hosts	Trimethoprim- sulphamethoxazole

## Manifestations cliniques d'orientation des différentes parasitoses

### Fièvre + diarrhée + myalgies et œdèmes

- trichinose

### Prurit anal

- oxyurose principalement
- tœniase ou anguillulose

### Fièvre + hépatomégalie

- *larva migrans* viscéral

### Manifestations oculaires

- *larva migrans* viscéral (par exemple d'une loase)

### Fièvre + douleurs abdominales

- fasciolose à la phase toxi-infectieuse

### Manifestations digestives ou urinaires

- bilharziose digestive (douleurs abdominales, cirrhose hépatique) ou urinaire (hématurie, dysurie)
- anisakiase (vives épigastalgies)
- fasciolose ou échinococose (douleurs hépatobiliaires, ictère)
- trichocéphalose, ascaridiase, tœniasis (douleurs abdominales troubles du transit)

### Manifestations pulmonaires (dyspnée, toux)

- phase de migration larvaire d'helminthes : ascaridiase, anguillulose
- localisation spécifique d'une hydatidose

### Anémie macrocytaire mégaloblastique

- botriocéphalose (tœniasis cosmopolite) avec son exceptionnelle mais très caractéristique carence en vitamine B12

## f. atteinte multi-organique

avec atteinte articulaire, purpura, multinévrite, atteinte rénale ou colique: rechercher de maladies auto-immunes et autres affections systémiques

- FAN, anti-DNA (lupus)
- facteurs rhumatoïdes, anti-CCP (polyarthrite rhumatoïde)
- ANCA (Churg et Strauss)
- ASCA (maladie de Crohn) = anticorps anti-Saccharomyces cerevisiæ

# Détection des atteintes organiques

Detection of eosinophil-mediated organ involvement <sup>†</sup>		
<i>Organ</i>	<i>In all patients</i>	<i>In symptomatic patients</i>
Cardiac	Serum troponin T, NT-proBNP, CK Electrocardiogram Echocardiogram	Cardiac MRI
Digestive, hepatic–splenic, pancreatic	Liver enzymes, lipase Abdominal CT	Endoscopy with biopsies
Pulmonary	Chest x-ray and CT Pulmonary function tests	Lung biopsy Bronchoalveolar lavage
Neurological		Brain MRI with DWI (or brain CT with contrast) Electroencephalogram Nerve conduction studies
Skin		Skin biopsy
Vascular		Angiography
Kidney, urinary tract	Urea, creatinine, urine dip-stick	Kidney/bladder biopsy Eosinophiluria

<sup>†</sup>Beyond thorough physical examination.  
 CK: Creatine kinase; CT: Computed tomography; DWI: Diffusion-weighted imaging; FDG: Fluorodeoxyglucose; HES: Hypereosinophilic syndrome;  
 L-HES: Lymphocytic variant HES; M-HES: Myeloproliferative variant-HES; RQ: Real-time quantitative.

**Table 2. Frequency of organ involvement in hypereosinophilic syndrome.**

	Series			
	HES		L-HES	
	Weller and Bubley (1994) [16]	Ogbogu <i>et al.</i> (2009) [17]	Roufousse <i>et al.</i> (2007) [13] <sup>†</sup> <i>CD3-CD4+</i>	<i>Other phenotypes</i>
Number of patients	105	188	35	21
Cutaneous (%)	58	69	94	67
Cardiac <sup>‡</sup> (%)	56	20	12	6
Neurological (%)	54	21	0	0
Digestive (%)	23	38	9	6
Pulmonary (%)	49	44	9	17
Splenic (%)	43	10	9	17
Hepatic (%)	30	NM	0	0
Ocular (%)	23	NM	0	0
Raynaud's (%)	NM	NM	12	0
Angioedema (%)	NM	NM	31	5

The 105 patients of the Weller and Bubley study [16] is the compilation of American [81], French [82] and British [83] series published between 1982 and 1989. Ogbogu and colleagues' series represents the largest published study of patients with different HES variants.

<sup>†</sup>In addition to the 38 patients reported by Roufousse *et al.* [13], nine patients from references [77,84–89] and nine unpublished patients referred to our center were also included.

<sup>‡</sup>In Weller and Bubley's series, cardiac and vascular involvement are considered together.

HES: Hypereosinophilic syndrome; L-HES: Lymphocytic variant HES; NM: Not mentioned.



# Pneumonies à éosinophiles

**Table 1.** Classification of the eosinophilic pneumonias in clinical practice

**Eosinophilic pneumonias of unknown cause**

Solitary idiopathic eosinophilic pneumonias<sup>#</sup>

Chronic eosinophilic pneumonia

Acute eosinophilic pneumonia

Eosinophilic pneumonia in systemic syndromes

Churg–Strauss syndrome

Idiopathic hypereosinophilic syndromes (lymphocytic or myeloproliferative variant)

**Eosinophilic pneumonias of known cause**

Eosinophilic pneumonias of parasitic origin

Eosinophilic pneumonias of other infectious causes

Drug-induced eosinophilic pneumonias

Allergic bronchopulmonary aspergillosis and related syndromes (including bronchocentric granulomatosis)

**Other pulmonary syndromes with possible eosinophilia**

Organising pneumonia, asthma, idiopathic pulmonary fibrosis, Langerhans' cell histiocytosis, malignancies

<sup>#</sup>: Löffler's syndrome may be idiopathic.

Table IV. The pulmonary eosinophilic syndromes.

Diagnosis	Peripheral eosinophilia	Radiology	BAL/biopsy findings	Systemic features
Chronic IEP	Marked	Peripheral opacities Migratory infiltrates	Marked eosinophilia	Non-specific, cough Weight loss
Acute IEP	Mild to absent	Bilateral infiltrates Pleural effusions	Marked eosinophilia	ARDS Recent-onset smoking
Churg–Strauss syndrome	Marked	Non-specific Migratory infiltrates Sometimes normal	Eosinophils Vasculitis Granulomas	Asthma, rhinosinusitis, peripheral neuropathy Cardiac and renal disease Palpable purpura
Hypereosinophilic syndrome	Marked	Interstitial infiltrates Pulmonary nodules Pleural effusions	Eosinophils	Cardiomyopathy Hepatosplenomegaly CNS vasculitis
Tropical pulmonary eosinophilia (microfilariae)	Marked	Bilateral opacities	Eosinophils	Fever, cough, hyper-reactive airways
ABPA	Moderate	Mucus plugs Centrilobular nodules Proximal bronchiectasis	Eosinophils Fungal hyphae Allergic mucin	Asthma, Rhinosinusitis Cystic fibrosis
Drug induced	Mild	Alveolar infiltrates Pleural effusions	Eosinophils	Fever, rash
Radiation induced	Mild to moderate	Unilateral infiltrates	Eosinophils	Fever, cough, dyspnoea

ARDS, acute respiratory distress syndrome; BAL, bronchoalveolar lavage; IEP, idiopathic eosinophilic pneumonia; ABPA, allergic bronchopulmonary aspergillosis; CNS, central nervous system.

**Table 4.** Diagnostic criteria for idiopathic acute eosinophilic pneumonia

1. Acute onset with febrile respiratory manifestations ( $\leq 1$  month, and especially  $\leq 7$  days duration before medical examination)
2. Bilateral diffuse infiltrates on imaging
3.  $P_{a,O_2}$  on room air  $\leq 60$  mmHg (8 kPa), or  $P_{a,O_2}/F_{i,O_2} \leq 300$  mmHg (40 kPa), or oxygen saturation on room air  $< 90\%$
4. Lung eosinophilia, with  $\geq 25\%$  eosinophils at BAL differential cell count (or eosinophilic pneumonia at lung biopsy when performed)
5. Absence of determined cause of acute eosinophilic pneumonia (including infection or exposure to drugs known to induce pulmonary eosinophilia); recent onset of tobacco smoking or exposure to inhaled dusts may be present

$P_{a,O_2}$ : arterial oxygen tension;  $F_{i,O_2}$ : inspiratory oxygen fraction; BAL: bronchoalveolar lavage.

# Parasitoses pulmonaires

Review

## Parasitic infections of the lung: a guide for the respiratory physician

H Kunst,<sup>1</sup> D Mack,<sup>2</sup> O M Kon,<sup>3</sup> A K Banerjee,<sup>4</sup> P Chiodini,<sup>2,5</sup> A Grant<sup>5</sup>

# Atteintes pulmonaires focales

**Table 1** Overview of parasitic lung diseases

Condition	Presentation	Imaging features	Geographical distribution	Incubation period	Investigations	Treatment
Focal disease						
Cystic lesions						
Hydatidosis	Symptoms due to mass effect Chest pain, cough, haemoptysis Hypersensitivity reaction Secondary abscess formation	Single or multiple lung cysts Pleural effusion Pneumothorax Hydro-pneumothorax	Wide distribution: Mediterranean borders, East and Central Asia, sub-Saharan Africa, Russia, China, South America	Months to decades after exposure	Hydatid serology positive in 50-60% Blood eosinophilia uncommon unless cyst leaking Aspiration and microscopy	Surgery Albendazole with or without praziquantel Aspiration
Coin lesions						
Dirofilariasis	Chest pain, cough, haemoptysis, wheezing Fever, malaise	Coin lesion with or without calcification	Pulmonary dirofilariasis reported from USA, Japan, Australia, South America	May be years after exposure	Blood eosinophilia uncommon Biopsy usually diagnostic	Surgical excision
Consolidation/pleural effusion						
Paragonimiasis	Pleuritic chest pain, cough, fever, haemoptysis	Pulmonary infiltrates Consolidation or cystic lesions Pleural effusion Pneumothorax	Asia, West Africa, Central and South America	1–27 months	Eggs in stool or sputum Eosinophilia in peripheral blood, pleural fluid or bronchoalveolar lavage Serology	Praziquantel
Amoebiasis	Right upper quadrant or shoulder tip pain Cough and bile expectoration	Pleural effusion, atelectasis, Empyema Amoebic lung abscess Secondary pneumonia Hepatobronchial fistula	Widely distributed	Weeks to years after exposure	Serology (may be negative, especially in early disease) Does not cause eosinophilia; usually does cause neutrophilia	Tinidazole (or metronidazole) followed by diloxanide furorate or paromomycin

# Infiltrats pulmonaires diffus transitoires

Diffuse disease  
Transient pulmonary  
infiltrates

Ascariasis

Cough, wheeze, dyspnoea,  
chest pain, fever  
Loeffler's syndrome  
Haemoptysis

Transient pulmonary  
infiltrates  
Bacterial pneumonia,  
eosinophilic pneumonia  
Pneumothorax

Worldwide in areas where  
sanitation is poor (faecal-oral  
transmission)

1–2 weeks from infection  
to onset of pulmonary  
symptoms

Larvae in pulmonary, gastric  
secretions  
Eggs in stool in established  
infection with adult worms,  
may be absent in larval  
migratory phase  
Blood eosinophilia during  
larval migration

Albendazole, mebendazole,  
piperazine, or pyrantel  
pamoate

Hookworm infection

Cough, wheeze, dyspnoea,  
chest pain, fever  
Loeffler's syndrome

Transient pulmonary  
infiltrates  
Eosinophilic pneumonia

Widely distributed: (infection  
usually by contact of bare  
feet with faecally  
contaminated soil)

Pulmonary manifestations  
start within 10 days of  
exposure, can continue for  
more than one month

Blood eosinophilia during  
migration, which may persist  
Eggs in stool in established  
infection with adult worms  
Eggs may be absent in larval  
migratory phase

Albendazole, mebendazole or  
pyrantel pamoate

Toxocariasis

Cough, dyspnoea, wheeze,  
asthma or bronchitis  
Hepatomegaly,  
splenomegaly, ocular lesions

Pulmonary infiltrates  
Secondary bacterial  
pneumonia

Worldwide distribution (adult  
worms live in gut of cats and  
dogs)

Several weeks

Peripheral blood eosinophilia  
common  
Eosinophilia in  
bronchoalveolar lavage  
Toxocara serology

Albendazole for visceral  
disease

Hookworm = ankylostome

# Atteintes alvéolaires interstitielles

Table 1 Continued

Condition	Presentation	Imaging features	Geographical distribution	Incubation period	Investigations	Treatment
Schistosomiasis	Acute disease: Katayama fever with cough, dyspnoea, rash, and arthralgias Loeffler's syndrome, pneumonitis Chronic disease: dyspnoea, pulmonary hypertension	Acute disease: transient reticulonodular changes Chronic disease: granulomatous lung disease, pulmonary hypertension, pulmonary AV fistulae	Africa, South America, south east Asia, China	Acute disease: 5–7 weeks after exposure. Chronic disease: years	Acute disease: blood eosinophilia common Acute disease: eggs in sputum, or bronchoalveolar lavage after 6 weeks Chronic disease: eggs in stool and/or urine ( <i>S haematobium</i> ) after about 6 weeks Schistosomal serology positive after 6-12 weeks	Praziquantel
Strongyloidiasis	In hyperinfection syndrome: asthma, ARDS, intra-alveolar haemorrhage	In hyperinfection syndrome: pulmonary infiltrates, miliary nodules, airspace opacities ARDS in severe disease, rarely granulomatous changes	Worldwide distribution where sanitation poor	Pulmonary symptoms may occur days after acute infection; hyperinfection may occur up to decades after infection	Blood eosinophilia common Larvae in stool or duodenal aspirate but not usually in sputum in chronic infection; In hyperinfection also in sputum, body fluids on microscopy or culture Strongyloides serology	Ivermectin, albendazole less effective
Tropical pulmonary eosinophilia (filariasis)	Cough, dyspnoea, wheeze Fever, malaise, weight loss	Bilateral reticulonodular shadowing Mediastinal lymphadenopathy	Asia, sub-Saharan Africa, South America	Up to years after leaving endemic area	Blood eosinophilia No microfilariae in peripheral blood Filarial serology (IgG)	Diethylcarbamazine with or without albendazole

# Traitement

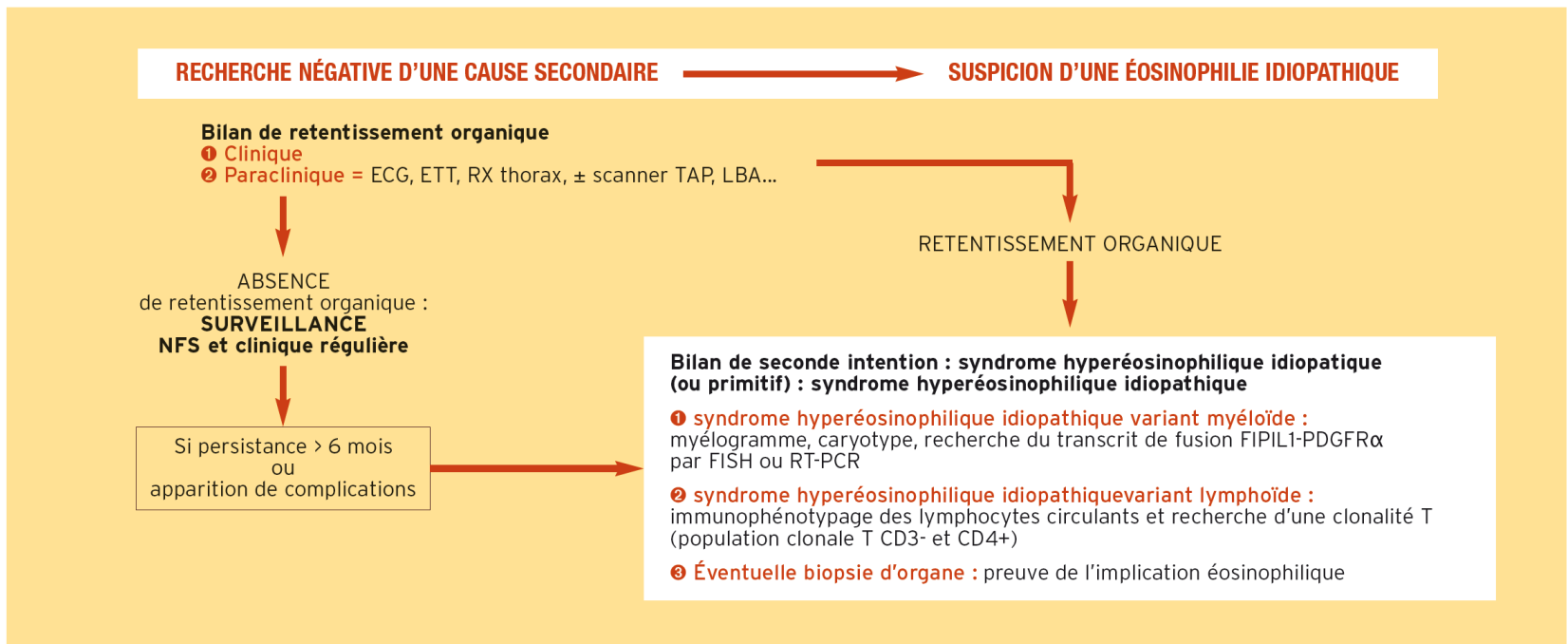


FIGURE 4 Principes du traitement.



## Situations d'urgence diagnostique et thérapeutique devant une éosinophilie parasitaire

### **Syndrome d'invasion larvaire sévère avec défaillances viscérales**

- Fièvre, éruption cutanée (urticaire), signes digestifs, syndrome de Löffler
- Myocardite (toxocarose, trichinose)
- Manifestations neurologiques

→ *Corticothérapie systémique en sus du traitement spécifique*

### **Syndrome d'hyperinfestation à anguillule (anguillulose maligne)**

- Invasion et défaillance multiviscérale (poumon, système nerveux central, cœur...) par les larves parasites, quasiment toujours fatale
- Terrain : sujet immunodéprimé par des traitements immunosuppresseurs ou une corticothérapie, infection par le virus HTLV1

→ *Toujours dépister, voire systématiquement traiter une possible anguillulose asymptomatique chez tout sujet ayant séjourné en zone tropicale, même 40 ans auparavant, avant l'administration de ces types de traitements*

### **Syndrome de lyse parasitaire**

- Traitement inapproprié d'une filariose avec charge parasitaire élevée
- Choc anaphylactique avec urticaire, asthme, encéphalopathie et défaillance multiviscérale

→ *En prévention : surveillance en milieu spécialisé, antihistamiques, corticothérapie, doses progressives et choix de traitement séquentiel par des molécules filaricides puis microfilaricides, le cas échéant*

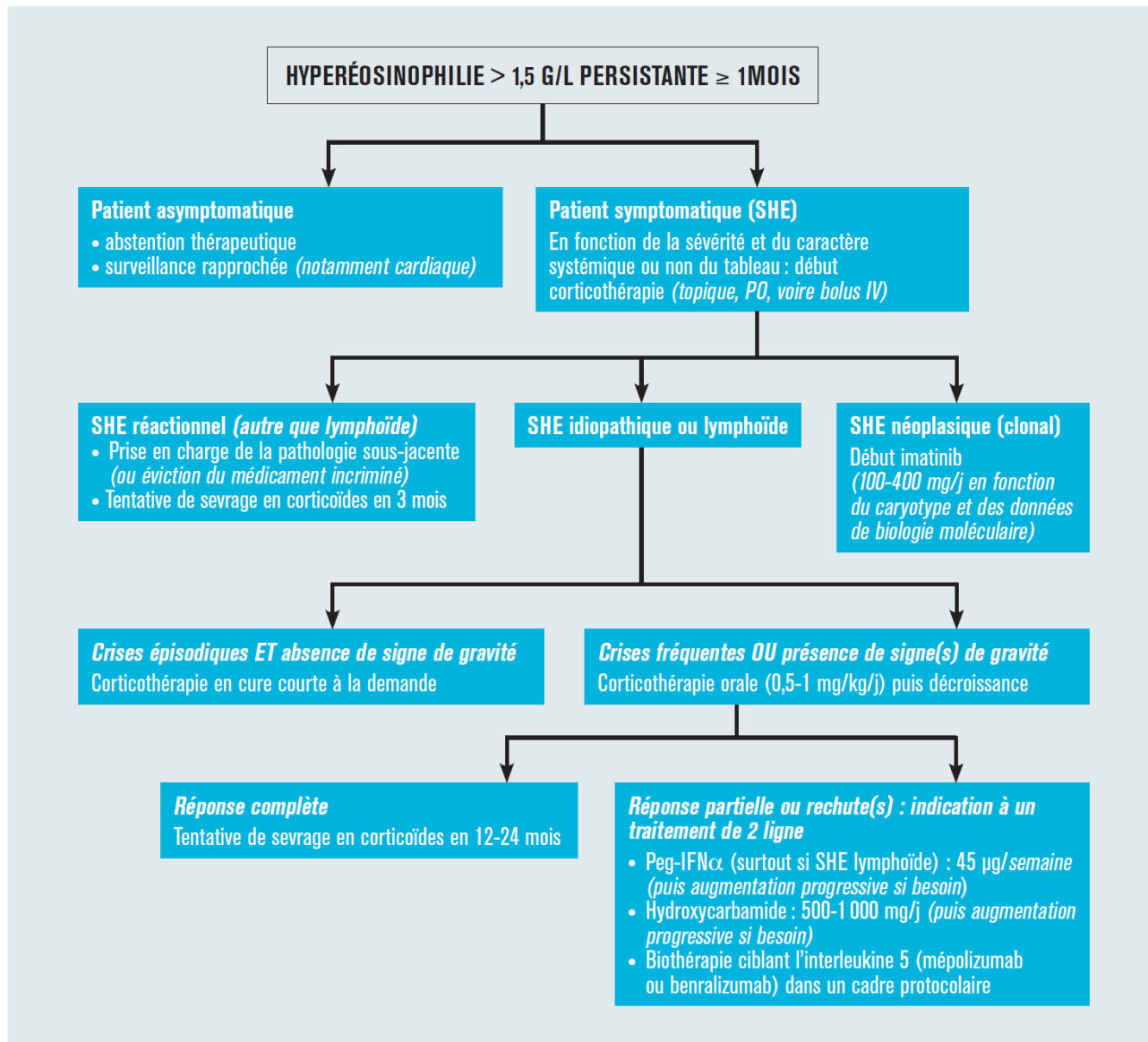


Figure 1. Proposition d'algorithme de prise en charge des patients suivis pour une hyperéosinophilie ou un syndrome hyperéosinophilique (SHE).